

Montefiore Pediatric Orthopedic and Scoliosis Center

Children's Hospital at Montefiore

Norman Otsuka MD – Eric Fornari MD

Jacob Schulz MD – Jaime Gomez MD – Christine Moloney PA

3400 Bainbridge Avenue, 6th Fl, Bronx, NY 10467 phone 718 920 2060 / fax 718 920 7799

1250 Waters Place, 11th Fl, Bronx, NY 10461

PEDIATRIC SCOLIOSIS

WHAT IS SCOLIOSIS?

Scoliosis is an abnormal curvature of the spine. The normal spine, when viewed from behind has no visible curve. When viewed from the side there will normally be a slight round back (kyphosis) in the upper back and a mild swayback (lordosis) in the lower back. When scoliosis develops (viewed from the behind) a curvature to the right or left will be seen (Figure 1). Associated with the abnormal curvature, there is also twisting of the spine. This twisting results in asymmetry of the rib cage. When viewed from the back a prominence of the ribs will be visible on the side of the curve.

Scoliosis may develop in one or more areas of the spine. Additionally, the curve patterns in scoliosis vary from short single curves to large double or triple curves (Figure 2).

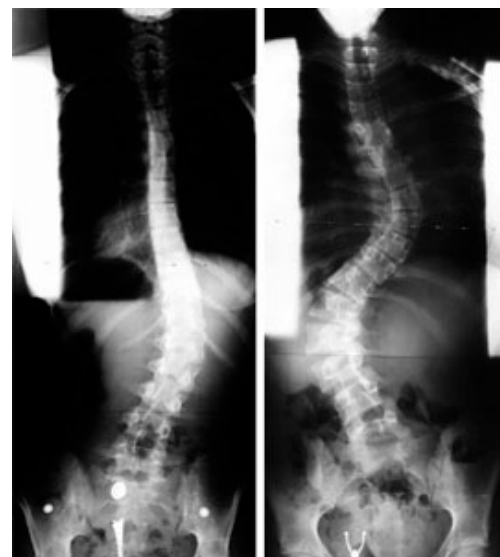

Figure 1

Figure 2

WHAT CAUSES SCOLIOSIS?

There are several causes of scoliosis. In some cases it results from an abnormal development of the bones in the spine. This is called **congenital** scoliosis and is present from the time of birth, although it may not be recognized until the deformity increases with growth. The primary sources of the deformity in this case are the abnormally shaped bones or asymmetrically fused bones in the spine that do not grow properly (Figure 3a). Another cause for scoliosis is poor neurologic or muscular control of the spine. In these circumstances, support from the muscles of the back is insufficient to maintain an erect spinal position. This type of **neuromuscular** scoliosis is seen in conditions such as cerebral palsy, spina bifida, muscular dystrophy, etc (Figure 3b).

The most common type of scoliosis in children and adolescents, however, results from unknown causes. When there is no underlying abnormality, the scoliosis is considered to be **idiopathic** (Figure 3c). Much investigation has gone into looking for the cause of scoliosis in these otherwise normal children, but so far no clear cause has been identified. There does appear to be an increased incidence of scoliosis within a family, suggesting some

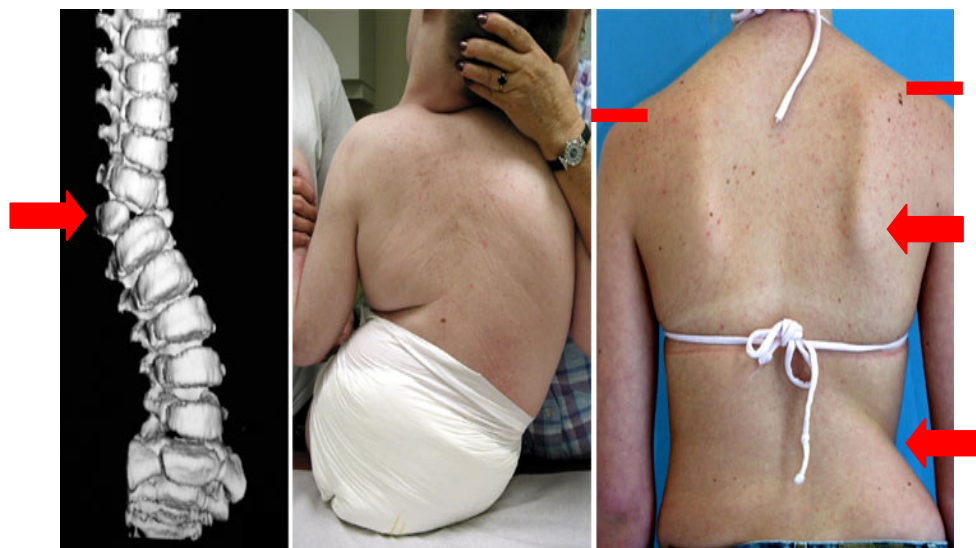

Figure 3a

Figure 3b

Figure 3c

genetic influence.

WHAT ARE THE CONSEQUENCES OF SCOLIOSIS?

The deformity of the spine, in cases of scoliosis, tends to increase with increasing growth of the spine. There are cases, however, in which no progression of the deformity occurs or the increasing size of the deformity is minimal. The shape of the body is altered depending on the scoliosis curve pattern. Concern develops in cases when the deformity is progressive. With large curves, trunk and chest deformity develop to a degree that ultimately inhibits normal lung and heart function (Figure 4a, b). For these reasons, treatment of scoliosis is recommended when a progressive curvature is detected.

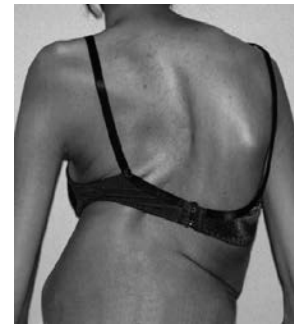


Figure 4a

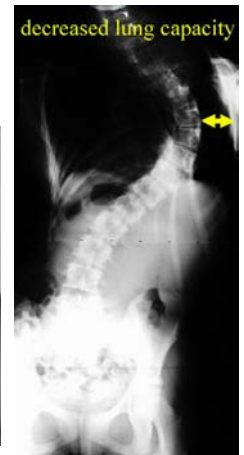

Figure 4b

HOW IS SCOLIOSIS ASSESSED?

The diagnosis of scoliosis is made by examining the shape of the back and trunk. As scoliosis progresses, a difference in the height of the shoulders may develop, as well as an asymmetry of the waistline and contour of the back (Figure 5a). Because of the rotational changes in the spine with the development of scoliosis, prominence of the ribs occurs. This can be seen most readily by examining the patient from behind when bent forward at the hips (Figure 5b). This forward bending test (Adam's test) is used in screening patients for scoliosis. In many states a scoliosis school screening program exists in which all children are examined for back and rib asymmetry. When a rib prominence is noted, a standing radiograph of the spine is recommended. The x-ray evaluation of the spine is made to determine the magnitude and pattern of spinal curvature. The angulation (measured in degrees) between the most tilted vertebrae is determined using the Cobb angle method (Figure 5c). It is this measure of scoliosis on which treatment recommendations are based.

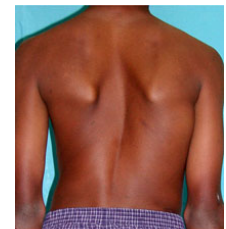


Figure 5a

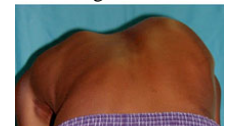

Figure 5b

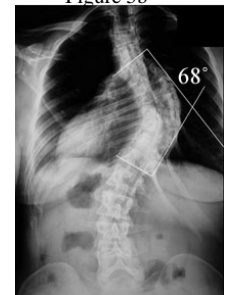

Figure 5c

RISK OF PROGRESSION:

In addition to the degree of scoliosis, it is important to assess the skeletal maturity of the patient. It is known that the risk of the curve enlarging is related to the amount of growth remaining in the skeleton and spine. This can be assessed in several ways. The first is a radiographic measure of the maturity of the skeleton, done by analyzing the growth centers of the pelvic bone. Other measures of remaining growth relate to the changes of puberty that can be assessed in both boys and girls. An additional helpful time point in girls relates to the onset of menstrual periods. The beginning of menstrual period suggests 1-1/2 to 2 years of remaining spinal growth. The estimate of the remaining spinal growth and the magnitude of the spinal curvature are used to predict the potential for scoliosis progression. The underlying cause of the scoliosis also plays a significant role in determining the likelihood of progression and need for treatment. It is recommended that a physician with expertise be involved in the care of a patient with scoliosis when the Cobb angle is greater than 15°.

HOW IS SCOLIOSIS TREATED?

The options for treating scoliosis include observation, the use of a brace (orthosis), or surgery. Currently, there is no evidence that exercise or spinal manipulation have a positive effect on preventing the progression of scoliosis.

HOW DOES BRACING HELP?

A brace used to control scoliosis is designed to apply external pressures to the trunk and pelvis, improving the alignment of the spine and allowing straighter growth of the spine (Figure 6a, b). Bracing of scoliosis is not helpful in patients who have completed or nearly completed their spinal growth. Bracing is indicated for patients with idiopathic scoliosis with curves between 25-45° and more than six months of skeletal growth remaining. While some curves improve, the goal of bracing is to **prevent progression of scoliosis**

There are several types of braces available (Figure 7a, b, c). All of the braces attempt to straighten the spine and are **most effective if worn full time**. The brace is made to fit the patient's trunk, providing pressure against the pelvis and rib cage to reduce the deformity. A brace maker (orthotist) is used to fit and adjust the brace accordingly. Initial brace wear may be uncomfortable, and a period of time is required to become accustomed to wearing the brace. X-rays are used to assess the correction of the spine in the brace and are taken periodically (every 3-4 months) to monitor the curve. The total length of time the brace will need to be worn is dependent on the remaining spinal growth. In general, the brace is worn until spinal growth has been completed. As this point is reached, the hours spent wearing the brace will be reduced and the brace ultimately discontinued.

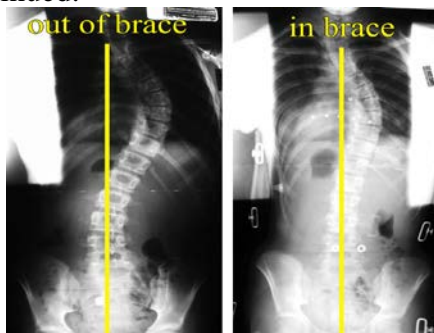


Figure 6a

Figure 6b

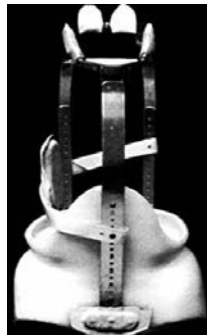

Figure 7a

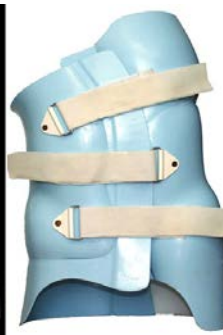

Figure 7b

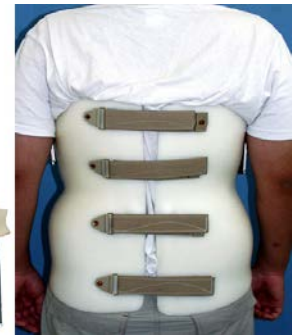

Figure 7c

WHEN IS SURGERY NEEDED?

The indication for proceeding with surgical treatment of scoliosis is dependent on multiple factors. The diagnosis and magnitude of the curve are the primary factors used in determining whether surgery is required to treat the deformity. Patients with idiopathic scoliosis, whose curves have progressed to greater than 40-50°, despite brace wear, are considered candidates for surgical treatment. Other important factors include the curve pattern, trunk imbalance, and skeletal maturity. The goal of surgical treatment is to provide a method for correcting the deformity, as well as preventing further progression of the curvature. Surgery is, therefore, useful in patients who have progressive curves that have not been controlled by brace treatment or who have curves that are too large to be amenable to brace treatment.

SUMMARY

Scoliosis is a curvature of the spine that most commonly affects adolescent girls. In some patients the deformity is progressive, necessitating treatment. Initial forms of treatment in the patient with remaining growth involve the use of a brace or orthosis. In some cases this is unsuccessful or the curve magnitude too

large for this to be effective, in which case surgical treatment is required. In either case, the goal of treatment is to limit progression of the deformity of the spine and trunk and obtain some correction of the deformity.