

Montefiore Pediatric Orthopedic and Scoliosis Center

Children's Hospital at Montefiore

Norman Otsuka MD – Eric Fornari MD

Jacob Schulz MD – Jaime Gomez MD – Christine Moloney PA

3400 Bainbridge Avenue, 6th Fl, Bronx, NY 10467 phone 718 920 2060 / fax 718 920 7799

1250 Waters Place, 11th Fl, Bronx, NY 10461

Legg-Calve-Perthes Disease of the Hip

Your child has been diagnosed as having Legg-Calve-Perthes disease. This is an attempt to briefly explain the nature of this hip disorder and our approach to treatment.

Legg-Perthes disease was described early in the 20th century following the invention of x-ray. Dr. Legg from Boston, Dr. Perthes from Germany, and Dr. Calve from France described the condition almost simultaneously. Thus, the odd name for the disorder.



Arthur T. Legg

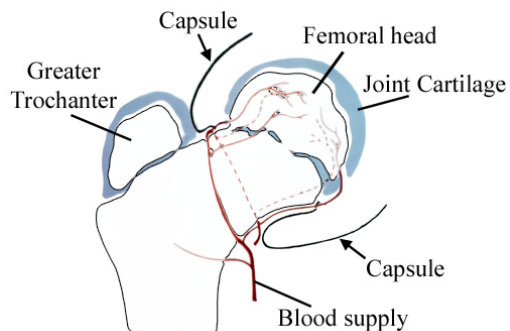


Jacques Calvé



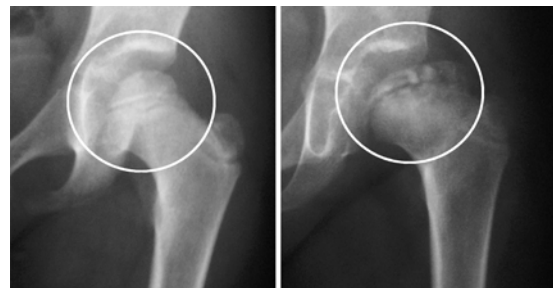
Georg Clemens Perthes

By custom in North America the name is shortened to Legg-Perthes disease. Despite careful studies we still do not know the exact cause of the condition. The reason for the x-ray changes and hip symptoms is an unexplained, temporary loss of blood supply to the ball (femoral head) of the hip joint. This ball is known as the femoral head.



The reason for the temporary loss of blood supply is unclear. It appears that some children, age 3 to 10 years, have a sensitive blood supply to the hip and that blood flow is somehow temporarily blocked. With loss of blood supply, the bone in the ball (femoral head), actually dies. This is followed by inflammation and irritation of the hip, with softening of the bone. This causes the limp and pain which leads to hip x-rays being performed and clarification of the diagnosis.

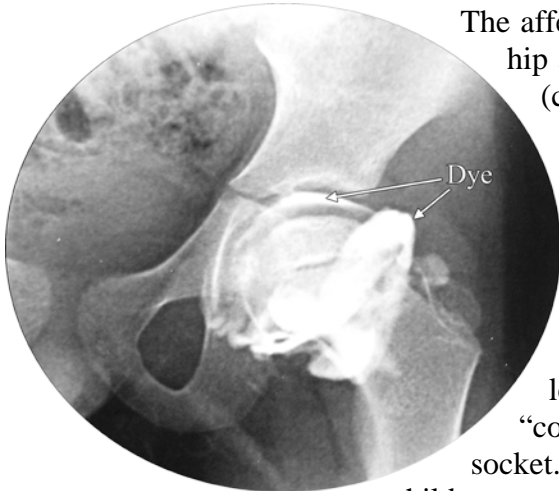
Once diagnosed, Legg-Perthes disease requires careful orthopedic evaluation. Some very young children with very minimal involvement do not require treatment and simply can be observed. In more serious cases vigorous treatment is required to prevent a change in the shape of the ball during the one to two year healing period in which the bone is soft and pliable and at risk for deformation.



normal hip

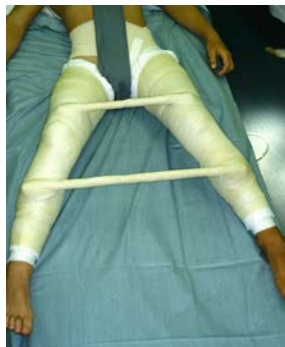hip with perthes

Fortunately the blood supply always returns to the femoral head with slow but certain bone healing. However, the hip usually requires treatment during the healing phase so that the ball maintains a relatively round shape. This minimizes the risk for premature arthritis in the hip joint.

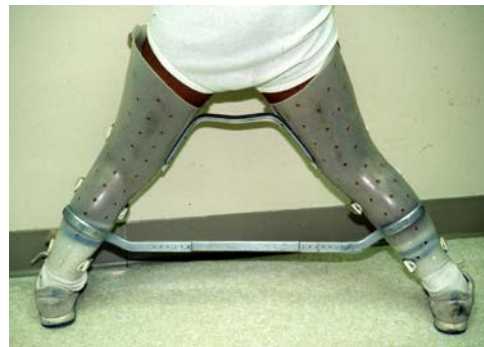

The affected hip is usually studied further by having a hip arthrogram that involves injecting an x-ray dye (contrast media) into the joint to allow careful study of the femoral head shape. This is done under general anesthesia at Children's Hospital. While under the same anesthesia, the child is placed into a pair of special leg casts (Petrie casts) that hold the hip in a healing position. Special props (sticks) are placed between the two leg casts to hold the legs in a wide spread position. This position "contains" the femoral head deeply within the socket. A rental wheelchair is arranged since many children cannot walk very well with these casts.

Following this initial study and treatment, the parents then have a choice: cast or brace treatment can be continued, however, the child must wear the cast or brace full time for a year to a year and a half.

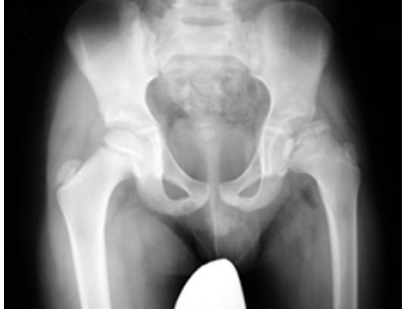


Petrie casts

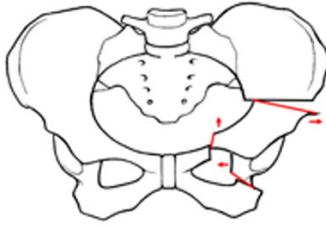


Petrie type brace (rarely used)

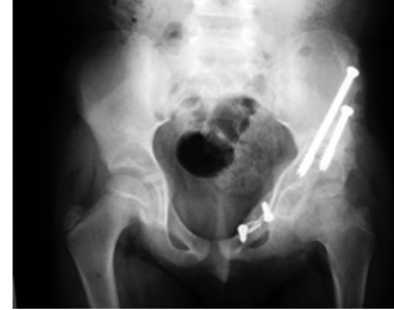We generally recommend a more practical approach, which allows the child to be more normal during this healing phase. This involves surgically changing the angle of the socket so that the ball is more deeply centered (contained) in the hip joint while the child is in a normal standing posture. This requires a formal surgical procedure. The procedure that we commonly use is known as a triple pelvic osteotomy, which is performed four to six weeks after the initial arthrogram study.



Before surgery – Lt hip

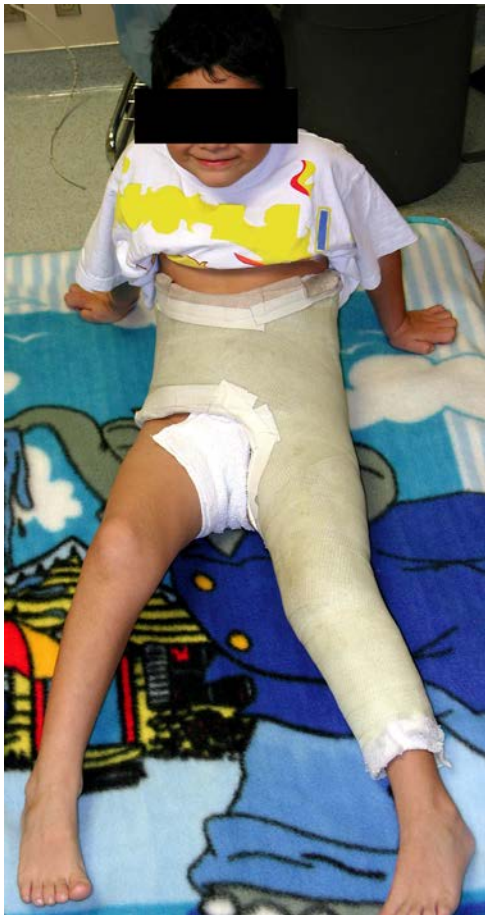

Purpose of Triple Osteotomy



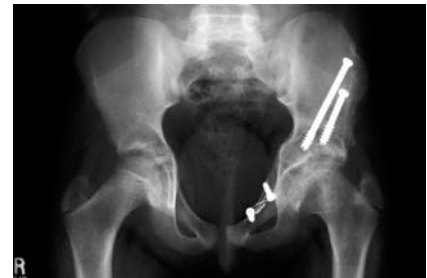After Surgery – Triple Osteotomy

Following this operation, the child again is placed in a cast. This cast surrounds the waist and is worn for six weeks. The child is also kept in a wheelchair while in this cast. Following cast removal the child normally remains in the wheelchair for additional 4 weeks and then uses crutches for several more weeks. The child then can stand and walk normally without braces, crutches or a cast during the one to two year healing period.



Hip spica cast for left hip Legg-Calve-Perthes

The healing process continues for a year or two and during this slow healing phase, the child is kept out of sports or vigorous activities. In rare cases, even with the corrective surgery, the child will have further hip symptoms and irritation and will have to go back into a cast for a temporary period. Occasionally further surgery is needed. Regular x-rays are taken (every three to six months) to monitor healing.



3 year follow up
Lt. Legg-Perthes

Overall, the prognosis for Legg-Perthes is good. After the one to two years of treatment, children return to normal physical activities and sports. Most patients will have no symptoms as a teenager. The long-term prognosis is also good, although in some cases the individual may develop hip arthritis at age 50 to 60.

In rare cases, the hip can become stiff and painful even as a teenager with a less than desired result.

We hope that this brief explanation will help you to better understand Legg-Perthes disease and it's treatment. We will be happy to discuss further details with you.